

# A CNN Approach to Central Retinal Vein Occlusion Detection

Jayanthi Rajee Bala, Mohamed Mansoor Roomi Sindha, Jency Sahayam, Praveena Govindharaj,  
and Karthika Priya Rakesh

**Abstract**—In the field of medicine there is a need for the automatic detection of retinal disorders. Blindness in older persons is primarily caused by Central Retinal Vein Occlusion (CRVO). It results in rapid, irreversible eyesight loss, therefore, it is essential to identify and address CRVO as soon as feasible. Hemorrhages, which can differ in size, pigment, and shape from dot-shaped to flame hemorrhages, are one of the earliest symptoms of CRVO. The early signs of CRVO are, hemorrhages, however, so mild that ophthalmologists must dynamically observe such indicators in the retina image known as the fundus image, which is a challenging and time-consuming task. It is also difficult to segment hemorrhages since the blood vessels and hemorrhages (HE) have the same color properties also there is no particular shape for hemorrhages and it scatters all over the fundus image. A challenging study is needed to extract the characteristics of vein deformability and dilatation. Furthermore, the quality of the captured image affects the efficacy of feature Identification analysis. In this paper, a deep learning approach for CRVO extraction is proposed.

**Keywords**—Blood vessels; Segmentation; Features; CRVO; Deep learning

## I. INTRODUCTION

**A**N occlusion in the microscopic blood-carrying veins that remove blood from the eyeball is known as a retinal vein occlusion (RVO). The retina contains a significant vein called the central visual vein as well as a vital organ known as the central retinal artery. The Central Retinal Vein Occlusion is brought a clot develops in the vein, allowing blood and excess liquid to flow into the eyeball. The macular, which is important for central vision, is surrounded by this material in the cornea regularly. If the capillaries in the eyes are too weak, an occlusion could result. The primary symptom of central retinal vein blockage is bleeding. One-sided disc enlargement, peripapillary intra retinal hemorrhages, dilated sinuous veins, and subretinal dot, blot, and fire hemorrhages are all seen on a dilated fundus examination. CRVO comes in two forms, ischemic and non-ischemic CRVO. It provides more active perception than Ischemic CRVO. Ischemic CRVO is a dangerous form of CRVO that causes vision loss and even ocular injury. Automatically detecting CRVO in its predetermined stage avoids blindness.

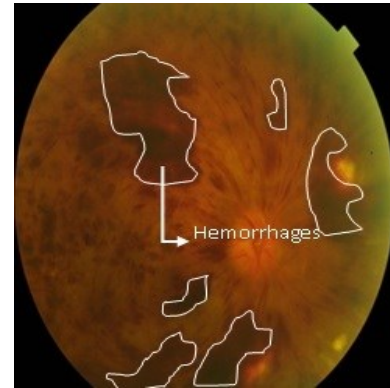


Fig 1. Central retinal vein occlusion image

People with diabetics and Hypertension are at the high risk of retinal bleed leading to Hemorrhages. Such HE's can be of various sizes, colors, and textures, are clinical features of CRVO. The primary objective of this method is to extract the hemorrhages. Some of the work related to extracting Hemorrhages were summarized below.

Bismite Choudhury et al. [1] developed a convolutional neural network to diagnose the CRVO. There is no demand for an additional feature extraction process. N. Rajapaksha et al. [2] suggested a method to detect hemorrhage density calculated from fundus pictures. Cosfire filters are also used in this. Daisuke Nagasato et al. [3] employed Deep Learning techniques, and Support Vector Machine (SVM) used to diagnose CRVO. Fuzzy c-means clustering was used by M. Ganesh et al. [4] to analyse the DRIVE database and identify occlusion with a 96.96% accuracy. Sasirekha N [5] used splat feature segmentation to detect retinal hemorrhages in color fundus images based on the pixel distribution. Sonali S et al [6] used channel extraction methods, with equalization of the histogram. Then Morphological operations were used to Identify Occlusion. This algorithm classifies the disease with a recognition rate of 89.06 .

Bae et al. [7] Proposed a method for the recognition of hemorrhages in fundus pictures by enhancement, matching of template, and thresholding techniques. Syna Sreng et al. [8] developed an algorithm that uses an enhancement technique, before finding interesting spots to locate fovea.

Authors are with Thiagarajar College of Engineering, Madurai, India (email: jayanthi@student.tce.edu, smmroomi@tce.edu,

jencysahayamxmd@gmail.com,  
karthikapriyatce@gmail.com)

praveenagovindharaj24@gmail.com,



Morphological operations were carried out to remove Capillaries in order to find HEs then to detect blood leakage Navkiran Kaur et al. [9] developed a method for improving the quality of the images, After that, the location of the cornea and optic disc were determined, as well as the capillaries and other features. Finally, the dark spots were found.

A method to determine the disease present in the fundus was suggested by Lorick Jain et al. [10]. With the aid of Deep CNN, the diseases can be identified after the images were cropped and their size changed. Sandra Morales et al.[11] proposed a technique to improve the image quality. LBP operators were used to extract features, which allowed for the identification of diabetics and AMD. The drawback here is the large consumption of time while applying segmentation. Jun Wu et al.[12] suggested a technique that combined aspects of two-dimensional (2D) Gaussian fitting with human visual features. Hemorrhage extraction is performed by watershed segmentation and assessed on the DIARETDB database.

Finding satisfactory results was a challenge for earlier researchers. There are no segmentation methods based on deep learning, only classifier-based methods that are currently available. In contrast to the numerous datasets used by all of the previous approaches, fewer datasets were employed in the proposed work. In this study, we used a semantic segmentation technique based on Mask R-CNN to detect haemorrhages in fundus images with central retinal vein blockage.

## II. METHODOLOGY

The proposed hemorrhage detection method consists of three main steps namely annotation, training, and testing as illustrated in fig 2.

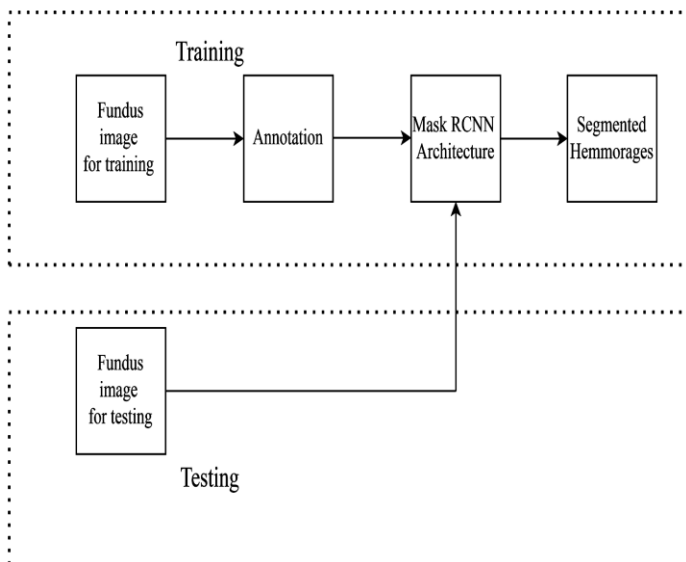


Fig 2. Block diagram CRVO detection

### A. Dataset Description

The dataset used for the proposed model has been taken from an open database of Joint Shantou International Eye Centre (JSIEC), Shantou city. The database consists of

1000 fundus images belonging to 39 different classes of retinal disorders. We have taken 22 images from the CRVO sample that were used for training and testing, along with 2 images of a healthy fundus.

The labeled images would then be sent to a computer vision system, which is also known as ground truth data. The most popular applications of image annotation are for object and area recognition, and picture segmentation. A sizable amount of annotated data is needed to train, assess, and test a machine-learning model for each of these applications. The data set of 22 fundoscopic CRVO images is annotated into 100 images. For each image, hemorrhages are considered as an attribute and their spots are selected and annotated. The annotated file is extracted in a single JSON format and used for further process.

### B. Mask R-CNN Model

Mask R-CNN identifies everything present in a picture down to the pixel level where each pixel in the image receives a label. The instance segmentation and feature computation are the two key elements of the Mask R-CNN network topologies. It incorporates the Core Networks, Area, RoI Alignment, and Network Mask Representation proposals. The standard ResNet design is ResNet-C4, while an option is ResNet with a feature pyramid network.

In this method, the coco dataset is used in the pre-trained model. Weights are gained from the Mask R-CNN coco model which also generates an h5 file. The Mask R-CNN network is then trained with the CRVO dataset generating another weighted h5 file. This model is an Enhanced Mask Recurrent convolutional model. The Enhanced Mask Recurrent convolutional model consists of four convolutional layers, four batch normalization, and one fully connected layer (FC) of size 1024. On a dataset of 100, this model takes 80 for training and 20 for testing validation with one class.

### C. Training

The data used to prepare an algorithm or machine learning model to predict the outcomes that your model was designed to foresee is known as training data. Using training datasets, algorithms are taught how to make predictions or carry out a task. A single JSON file containing 80 annotated photos from makesense.ai is exported for training and fed to the Mask R-CNN architecture. The hyperparameters used in the training procedure are epoch and learning rate. Training is carried out for various epochs and learning rates. The training is carried out in the Google CoLab.

### D. Testing

A set of data known as the test set is used to evaluate the model's performance using performance measures. 20 Images were used for testing. Testing of images is different from training.

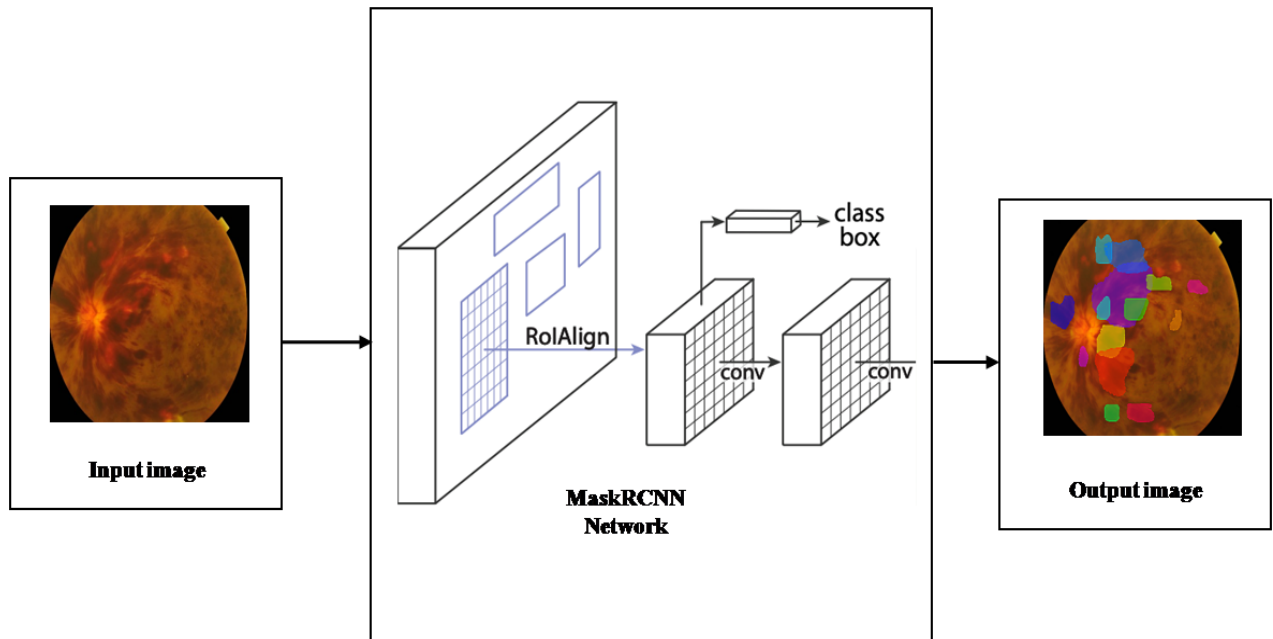


Fig 3.Mask R-CNN Architecture

E. Hyper Parameters

Hyperparameters are variables that regulate the network's topology. Table I displays the hyperparameter for this model. Between the input and output layers are layers known as hidden layers. Regularization methods can increase the accuracy of several hidden units inside a layer. The reduced unit count runs the risk of underfitting hemorrhage identification

TABLE I  
MASK R-CNN MODEL HYPERPARAMETERS

Epoch	Learning rate
Backbone	Resnet101
Image size	800x1024
Batch size	8
Optimizer	Keras
Rate	0.0001
RPN NMS threshold	0.7
Epoch	10
Anchor scales	[32,64,128,256,512]
Anchor Aspect ratio	[0.5,1,2]
Momentum Learning	0.9

The data set is trained using counts of 5, 10, 15, and 20. Each epoch takes about 800 seconds to complete and consists of 1000 steps. During training, The learning rate is set at 0.01 to 0.0001 and the loss and outcome are examined.

III. RESULTS AND DISCUSSIONS

The data set, which consists of 22 fundus images with CRVO, was gathered from the Joint Shantou International Eye Centre's (JSIEC) online database. These images are enhanced to create 100 images. MakeSense.ai is used to manually annotate the impacted fundus images. A free and open-source annotation tool with a GPLv3 licence is called Makesense.ai.

Make sense supports all types of annotations, including line, rectangle, polygon, and point. YOLO, VOC XML, VGG JSON, and CSV are just a few of the formats in which the labels can be exported. Hemorrhages alone are taken into account and labelled in annotation. is displayed in fig.2. The file with annotations is extracted in JSON format.

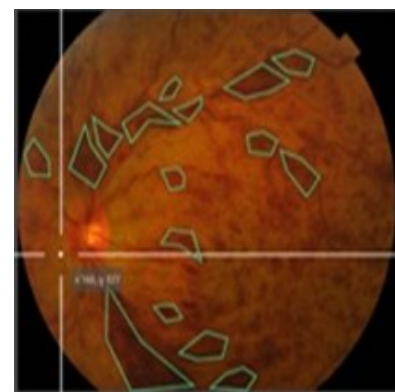


Fig 4.Annotated fundus image

The images are trained using a mask R-CNN architecture using an annotated file. Python code is used for the training and testing on the Google CoLab platform. With the GPU count set to 1, training is carried out first with 10 epoch and a learning rate of 0.001, then with epoch 20 and a learning rate of 0.0001. Figure 3 depicts the afflicted area and matching mask for Central Retinal Vein Occlusion. During validation, a random image from the training dataset is checked for the presence of hemorrhage. Hemorrhages and the confirmation score are both reported in the final result. The proposed approach, which has a maximum confirmation score of 1.000, is depicted in Figure 4.

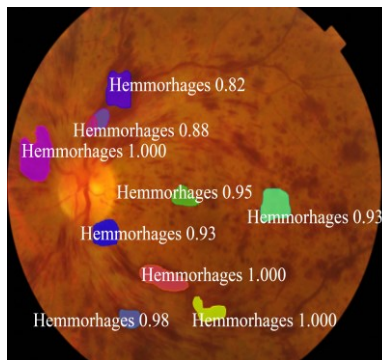


Fig 5. Validation result

There will be training loss and validation loss for each period. Table II shows the degree of accuracy. Epoch, Learning rate, Batch size, and Testing Loss were taken into account in this case. With a learning rate of 0.01 and a batch size of 4, epoch 5's testing loss is 0.34 and accuracy is 63%. The CRVO was then detected in the tested images. Epoch 10's accuracy is 72%, testing loss is 0.28, learning rate is 0.001, and batch size is 4. It is obvious that as the number of epochs increases, the loss decreases and the result is more accurate. The accuracy is 82%, testing loss is 0.18, learning rate is 0.0001, and block size is 8 in epoch 15. In epoch 20, the accuracy is 96%, the testing loss is 0.28, and the learning rate is 0.001 with a block size of 8. From the above table, epoch 20 produces good CRVO detection.

TABLE II  
TUNING OF HYPERPARAMETERS

Epoch	Learning rate	Batch size	Testing loss
5	0.01	4	0.34
10	0.001	4	0.28
15	0.0001	8	0.18
20	0.0001	8	0.04

The Mask R-CNN network is trained with epoch 10 and a learning rate of 0.0001 before being used to test the fundoscopic images. Most haemorrhages associated with CRVO are seen in the initial testing. The testing is then completed using an epoch of 20 and a learning rate of 0.0001. Epoch 20 provides superior outcomes by spotting the location in the fundus image as depicted in fig. 7.

Training a mask R-CNN is easy and transparent. Mask R-CNN outperforms all currently accessible single-model entries for every objective. The IOU computed shows the efficacy of the proposed method as evidenced in table III where the IOU score of 93.37[13] indicates edema is detected. Our proposed method detects the hemorrhage parts in CRVO images using mask RCNN with an IOU score of 91.15. Hemorrhages were also detected using U-Net with an IOU score of 76.61.[14] The saliency map and U net detected the disease of Micro Microaneurysm with an IOU score of 90.19.[14]

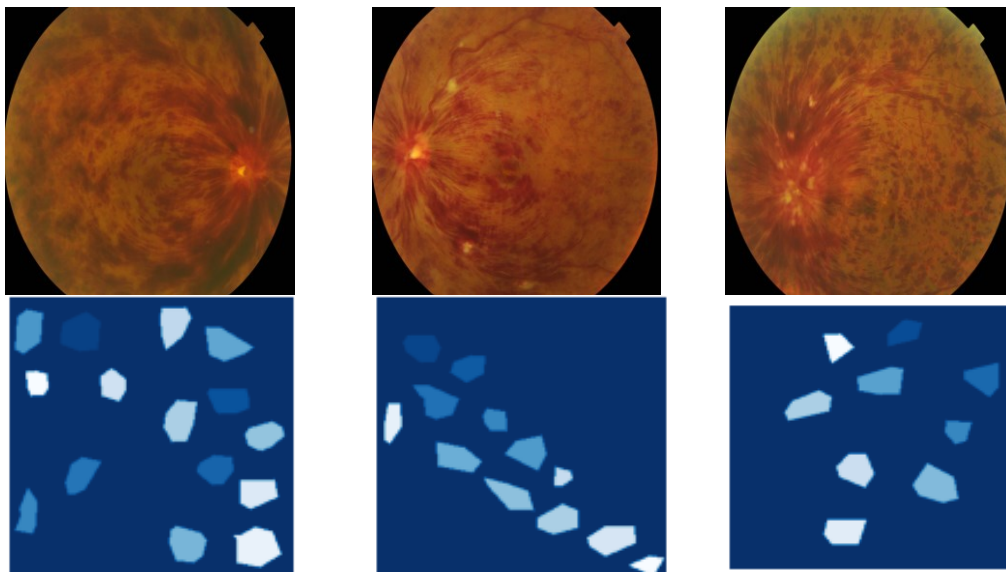


Fig 6. CRVO affected image and their corresponding mask

**RESULTS OF CRVO IMAGES**

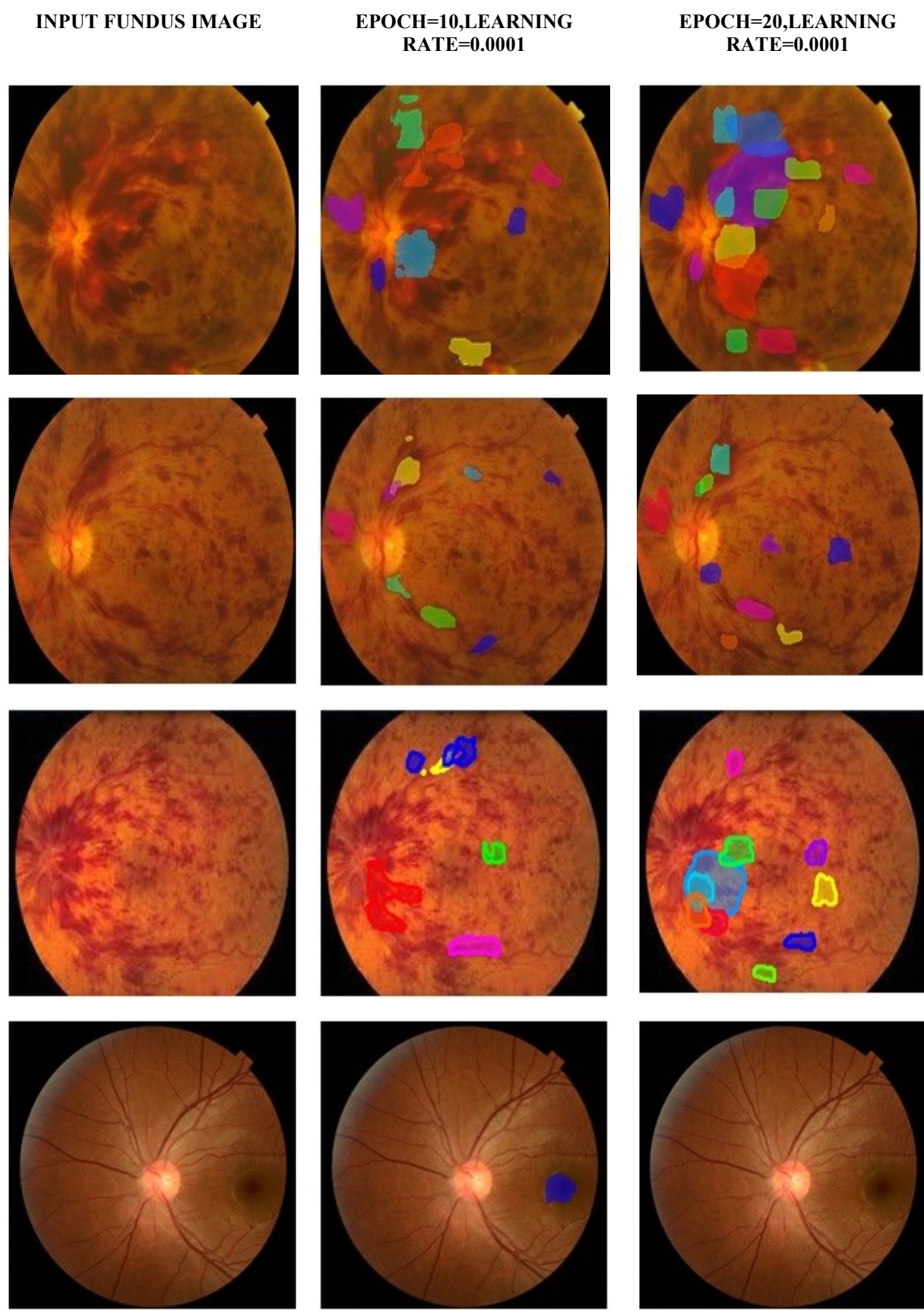


Fig 7. CRVO Detected Results

TABLE III  
COMPARISON TABLE OF DISEASE IDENTIFIED

Method	Disease Identified	Database	IOU
Mask R-CNN	Edema	AI Challenger 2018 global challenge, IDRID and DIARETDB1	93.37
U-NET	Hemorrhage	IDRID and DIARETDB1	76.61
Saliency map and U net	Microaneurysm	IDRID	90.19
Proposed(Mask RCNN)	Central retinal vein occlusion	JSIEC data set	91.15

### CONCLUSION

There is a higher prevalence of retinal conditions in society, including diabetic retinopathy, glaucoma, macular degeneration and edema, and vein blockage. Given that there has been less research on it than other retinal illnesses, our work primarily focuses on the identification of central retinal vein blockage. With 20 epoch and a learning rate of 0.0001 using the kaggle.com dataset, the proposed method successfully identified haemorrhages on their own. Mask RCNN will be changed in the future to identify cotton wool patches in addition to haemorrhages, which will be used to detect BRVO with CRVO.

### ACKNOWLEDGEMENTS

The authors express their sincere gratitude to the Thiagarajar college of engineering(TCE) for supporting us to carry out this research work. Also the financial support from TCE under Thiagarajar Research Fellowship Scheme.(File no: TRF/July 2021/03).

### REFERENCES

- [1] Bismita Choudhury, Patrick H.H. and Valliappan Raman, "Automated Detection of Central Retinal Vein Occlusion Using Convolutional Neural Network", Springer International Publishing AG, 2017 [https://doi.org/10.1007/978-3-319-63917-8\\_1](https://doi.org/10.1007/978-3-319-63917-8_1)
- [2] N.Rajapaksha, L.Ranathunga, K.M.P.K Bandara, "Detection of Central Retinal Vein Occlusion Using Guided Salient Features", IEEE-Digital Image Computing: Techniques and Applications (DICTA). 2019 <https://doi.org/10.1109/DICTA47822.2019.8945864>
- [3] Daisuke Nagasato, Hitoshi Tabuchi, Hideharu Ohsugi, Hiroki Masumoto, Hiroki Enno, Naofumi Ishitobi, Tomoaki Sonobe, Masahiro Kameoka, Masanori Niki, Ken Hayashi, and Yoshinori Mitamura, "Deep Neural Network-Based Method for Detecting Central Retinal Vein Occlusion Using Ultra Wide-Field Fundus Ophthalmoscopy", Hindawi- Journal of Ophthalmology 2018. <https://doi.org/10.1155/2018/1875431>
- [4] Ganesan P, M.Ganesh, L.M.I. Leo Joseph, V. Kalist, "Central Retinal Vein Occlusion: An Approach for the Detection and Extraction of Retinal Blood Vessels", 2018 Journal of Pharmaceutical Sciences and Research 2018, <https://www.jpsr.pharmainfo.in/Documents/Volumes/vol10Issue01/jpsr10011840.pdf>
- [5] Arun G, N Sasirekha, "Detection of Retinal Hemorrhage in Color Fundus Image using Splat Feature Segmentation", IEEE Sponsored 2nd International Conference on Innovations in Information Embedded and Communication Systems ICIECS 15, 2015, <https://doi.org/10.1109/ICIECS.2015.7192928>
- [6] Sonali S. Gaikwad, Ramesh R. Manza, "Detection of Hemorrhage from Retinal Images Using Digital Image Processing Techniques", International Journal of Engineering Development and Research (IJEDR) 2017. <https://www.ijedr.org/papers/IJEDR1704038.pdf>
- [7] Jang Pyo Bae, Kwang Gi Kim, Ho Chul Kang, Chang Bu Jeong, Kyu Hyung Park, and Jeong-Min Hwang, "A Study on Hemorrhage Detection Using Hybrid Method in Fundus Images", Journal of Digital Imaging June 2011. <http://dx.doi.org/10.1007/s10278-010-9274-9>
- [8] Syna Sreng, Noppadol Maneerat, Don Isarakorn, Kazuhiko Hamamoto, Ronakorn Panjaphongse, "Automatic Hemorrhages Detection Based on Fundus Images", 7th International Conference on Information Technology and Electrical Engineering (ICITEE) 2015. <https://doi.org/10.1109/ICITEE.2015.7408951>
- [9] Navkiran Kaur, Jasmeen Kaur, Mausumi Acharyya, Nishant Kapoor, Somsirsa Chatterjee, Sheifali Gupta, "A Supervised Approach for Automated Detection of Hemorrhages in Retinal Fundus Images", Institute of Electrical and Electronics Engineers (IEEE) 2016. <https://doi.org/10.1109/WECON.2016.7993461>
- [10] Lorick Jain, H V Srinivasa Murthy, Chirayush Patel, Devansh Bansal, "Retinal Eye Disease Detection Using Deep Learning", fourteenth International Conference on Information Processing (ACINPRO)-IEEE2018. <https://doi.org/10.1109/ACINPRO43533.2018.9096838>
- [11] Sandra Morales, Kjersti Engan, Valery Naranjo, "Retinal Disease Screening through Local Binary Patterns", IEEE Journal of Biomedical and Health Informatics 2015. <https://doi.org/10.1109/JBHI.2015.2490798>
- [12] Jun Wu , Shihao Zhang , Zhitao Xiao, "Hemorrhage detection in fundus image based on 2D Gaussian fitting and human visual characteristics", Optics and laser technology, Elsevier <https://doi.org/10.1016/j.optlastec.2018.07.049>
- [13] Haiying Xia, Fuyu Zhu, "Expanded Mask R-CNN's Retinal Edema Detection Network", ISICDM'19, August 24–26, Xi'an, China. 2019. <http://dx.doi.org/10.1145/3364836.3364869>
- [14] Guodong Zhang, Hasindu Maduranga Suraweera, Adevian Fairuz Pratama, Dazhe Zhao, Zhaoxuan Gong, and Wei Guo, "Automatic Segmentation of Microaneurysm in Retinal Fundus Images", 2020. <http://dx.doi.org/10.1088/1757-899X/768/7/072023>
- [15] Ayoub Skouta, Abdelali Elmoufidi, Said Jai, Andaloussi and Ouail Ouchetto, "Hemorrhage semantic segmentation in fundus images for the diagnosis of diabetic retinopathy by using a convolutional neural network", Skouta et al. Journal of Big Data network 2022. <http://dx.doi.org/10.1186/s40537-022-00632-0>